

CICL Field Center Manual of Operations



BRIGHAM
AND
WOMEN'S
HOSPITAL



Harvard Medical School

Cardiac Imaging Core Lab | Brigham and Women's Hospital
PB-A 100, 20 Shattuck Street, Boston, MA 02115, USA
Ph. 617 525 6730 | Fax. 617 582 6027



Hispanic Community Health Study – Study of Latinos

HCHS/SOL Cohort – Visit 2

Echocardiography Field Center Manual of Operations

Scott D. Solomon, MD, Director
Brigham and Women's Cardiac Imaging Core Laboratory
Boston, MA

V5.1 11/19/2015

CONFIDENTIALITY STATEMENT

The information contained in this document, especially any unpublished material, is the property of Brigham and Women's Hospital Cardiac Imaging Core Lab and is therefore provided to you in confidence as a member of the above-referenced study staff. It is understood that this information will not be disclosed to others without written authorization from Scott D. Solomon, MD, Director of the Cardiac Imaging Core Lab.

Table of Contents

Section	Page
I. Introduction	3
II. Study-wide process overview	4
III. Sonographer certification	5
IV. Submission of Studies from the Field Center to the Reading Center	6
V. Instructions for Electronic Transfer of Studies to the Reading Center	7
VI. Instructions for Conducting Studies	10
VII. Guidelines for Image Optimization	11
VIII. Echocardiogram Protocol: Required Views	13
IX. Detailed Review of Protocol Required Views	14
Parasternal long axis	15
Parasternal short axis	17
Apical 4 chamber	21
Apical 5 chamber	28
Apical 2 chamber	30
Apical 3 chamber	31
Subcostal view	31
X. Reporting of Critical Results	32
XI. Echocardiography Reading Center Contact Information	33

I. Introduction

The National Heart, Lung and Blood Institute (NHLBI) initiated the Hispanic Community Health Study/Study of Latinos (HCHS/SOL) in 2006, with the recruitment of approximately 16,000 Hispanic/Latino adults from 4 communities across the country. In addition to being disproportionately affected by diabetes, and the component conditions of the metabolic syndrome, Hispanics remain unfavorably affected by health care disparities that predispose to all major adverse events. Therefore, Hispanics represent a population that is particularly vulnerable to cardiovascular outcomes, including heart failure (HF). The performance of echocardiography at the HCHS/SOL Visit 2 examination offers the opportunity to identify the manifestations of cardiac dysfunction that precede overt HF in the at-risk, understudied population of Hispanic/Latino Americans. Whereas prior and predominantly cross-sectional studies have investigated the demographic, social/culture, and clinical factors associated with HF in Hispanics/Latinos, echocardiography in HCHS/SOL will be the first to provide comprehensive, detailed phenotyping of pre-clinical cardiac disease in a large sample of Hispanics/Latinos with representation across age, sex, ethnic/cultural subgroups, and geographic regions.

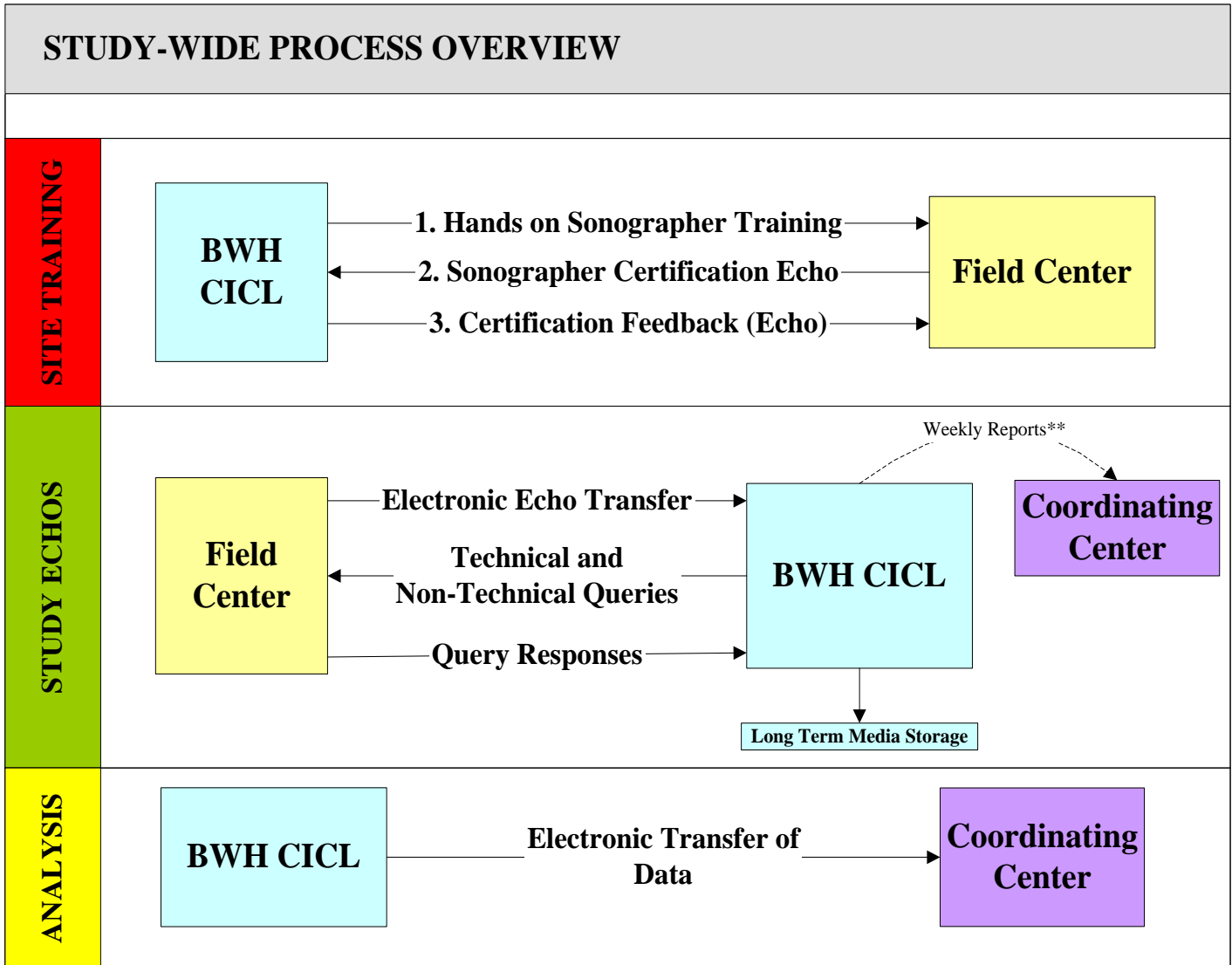
The Brigham & Women's Hospital Cardiac Imaging Core Laboratory (CICL) in Boston, Massachusetts will serve as the Echocardiography Reading Center for HCHS/SOL Visit 2. This manual contains key information Field Centers need to perform high quality study echocardiograms.

OBJECTIVES	
Echocardiography	<ul style="list-style-type: none"> Echocardiographic examinations will be performed to estimate myocardial structure and performance including but not limited to: left and right ventricular systolic function, left ventricular end diastolic volume (LVEDV), left ventricular end systolic volume (LVESV), left ventricular mass, left atrial size, LV diastolic function, mitral inflow pulsed wave Doppler (E wave, A wave), isovolumic relaxation time (IVRT), tricuspid regurgitation (TR) velocity.
Cardiac Imaging Core Lab	<ul style="list-style-type: none"> To provide high quality reproducible quantitative analysis of study echocardiograms
Field Center Manual of Operations	<ul style="list-style-type: none"> To instruct field centers on how to perform and send study echos to the Cardiac Imaging Core Lab (CICL).

ROLES AND RESPONSIBILITIES	
Field Centers	<ul style="list-style-type: none"> Perform high-quality study echocardiograms per the protocol contained in this document
Cardiac Imaging Core Lab	<ul style="list-style-type: none"> Receive, review and analyze study echos. Train and certify each field center sonographer. Provide field centers quality feedback on echos. Serve as a resource for sites for all echo-related questions.

II. Study-Wide Process Overview

Field centers will electronically transmit echos directly to the Cardiac Imaging Core Lab (CICL). Below is a basic diagram to describe the study wide process that will occur.



III. Sonographer Certification

The purpose of certification is to ensure consistency in how echocardiograms are performed study-wide and to ensure performance of the highest quality echocardiograms. Any sonographer who will be performing study echocardiograms must first submit two certification studies performed in accordance with the protocol described in this manual and transferred electronically to the CICL for review and certification.

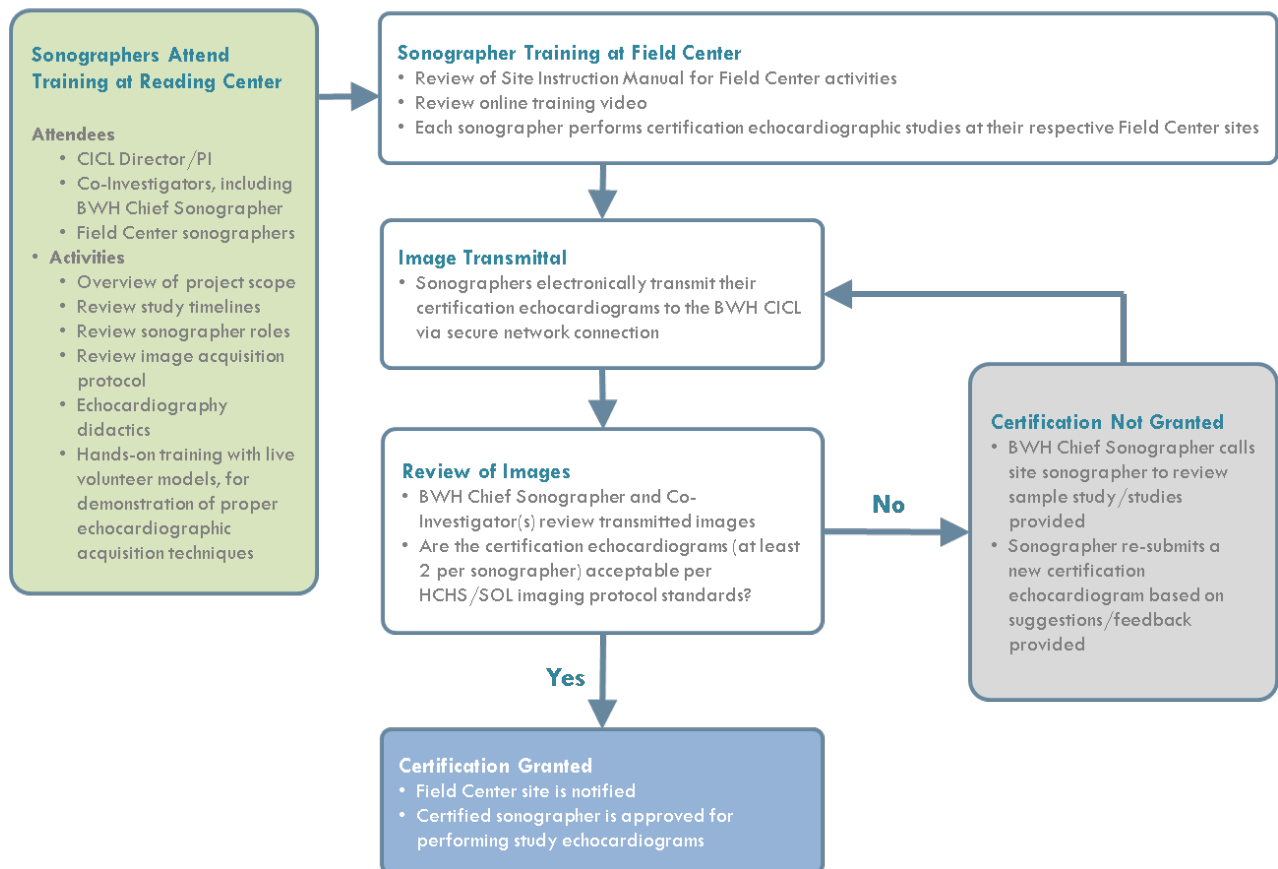
Studies will be scrutinized for adherence to protocol, acquisition of all required views, and image quality. Itemized direct written feedback and suggestions from the technical project manager will be provided for each study submitted. This is intended to address any individual equipment or operator dependent problems that may arise. Sonographers will have the opportunity to re-submit a sample protocol study should the initial submission be inadequate. Following submission of an adequate sample study, the sonographer will be officially certified and will receive feedback documenting this.

New Field Center sonographers starting during the study period will be required undergo the certification process outlined above by submitting 2 sample protocol studies in order to demonstrate the ability to perform a technically adequate protocol study and the knowledge to successfully transmit this data to the CICL.

A general outline of the process is outlined below. Prior to performing and submitting a sample study for certification, the following steps are recommended:

1. Read and review the Site Instruction Manual and Pocket Guide. An instructional video will be available on the HCHS/SOL Visit 2 Echocardiography Reading Center website as an additional resource. This is considered supplemental and is not a requirement to receive certification. These materials will be made available on the CICL web portal for HCHS/SOL.
2. Contact the CICL for any questions before performing and submitting the certification echo to the CICL.

Sonographer Certification Process Overview



IV. Submission of Studies from the Field Center to the Reading Center

All HCHS/SOL Visit 2 echocardiograms will be transmitted electronically from Field Centers to the Echocardiography Reading Center via a secure VPN transfer system as detailed in Section V: Instructions for Electronic Transfer of Studies to the Reading Center. Field center staff will receive electronic confirmation (by email) upon successful receipt of each echocardiogram by the Reading Center.

Reading Center Feedback to Field Centers

The CICL will continuously monitor the adequacy and quality of all studies received according to the criteria outlined in the table below:

Criteria for Evaluating Quality of Echocardiographic Images Received from Sites

Criteria for Evaluating Image Quality	
View	Scoring
Parasternal long axis view	<ul style="list-style-type: none"> • 2 points: Image is on axis and endocardial border well visualized in all anatomic segments of the main structures imaged (e.g. all 4 segments of the LV) • 1 point: Image is not completely on axis, or the endocardial border is well visualized in most but not all anatomic segments of the main structures imaged (e.g. only 5/6 anatomic segments of the LV) • 0 points: Image is completely off axis, or endocardial border not well visualized >15% of anatomic segments of the main structures imaged
Apical 4 chamber view	<ul style="list-style-type: none"> • 2 points: Image is on axis and endocardial border well visualized in all anatomic segments of the main structures imaged (e.g. all 6 segments of the LV) • 1 point: Image is not completely on axis, or endocardial border is well visualized in most but not all anatomic segments of the main structures imaged (e.g. only 5/6 anatomic segments of the LV) • 0 points: Image is completely off axis, or endocardial border not well visualized >15% of anatomic segments of the main structures imaged (e.g. there is dropout of ≥ 2 (of 6) anatomic segments of the LV)
Short axis at the mid-ventricular level	<ul style="list-style-type: none"> • 2 points: Image is on axis and endocardial border well visualized in all anatomic segments of the main structures imaged (e.g. all 6 segments of the LV) • 1 point: Image is not completely on axis, or endocardial border is well visualized in most but not all anatomic segments of the main structures imaged (e.g. only 5/6 anatomic segments of the LV) • 0 points: Image is completely off axis or endocardial border not well visualized >15% of anatomic segments of the main structures imaged (e.g. there is dropout of ≥ 2 (of 6) anatomic segments of the LV)
Apical 2 chamber view	<ul style="list-style-type: none"> • 2 points: Image is on axis and endocardial border well visualized in all anatomic segments of the main structures imaged (e.g. all 6 segments of the LV) • 1 point: Image is not completely on axis, or endocardial border is well visualized in most but not all anatomic segments of the main structures imaged (e.g. only 5/6 anatomic segments of the LV) • 0 points: Image is completely off axis or endocardial border not well visualized >15% of anatomic segments of the main structures imaged (e.g. there is dropout of ≥ 2 (of 6) anatomic segments of the LV)
Doppler views	<ul style="list-style-type: none"> • 2 points: Clear signals captured over at least 3 cardiac cycles for all Doppler measures • 1 point: Clear signals captured over at least 2 cardiac cycles for most Doppler measures • 0 points: Absent or unclear signals captured for most Doppler measures
Criteria for Scoring	
Grading	Total Points
Good quality	9-10 points

Acceptable quality	6-8 points
Fair quality	4-5 points
Poor quality	≤3 points

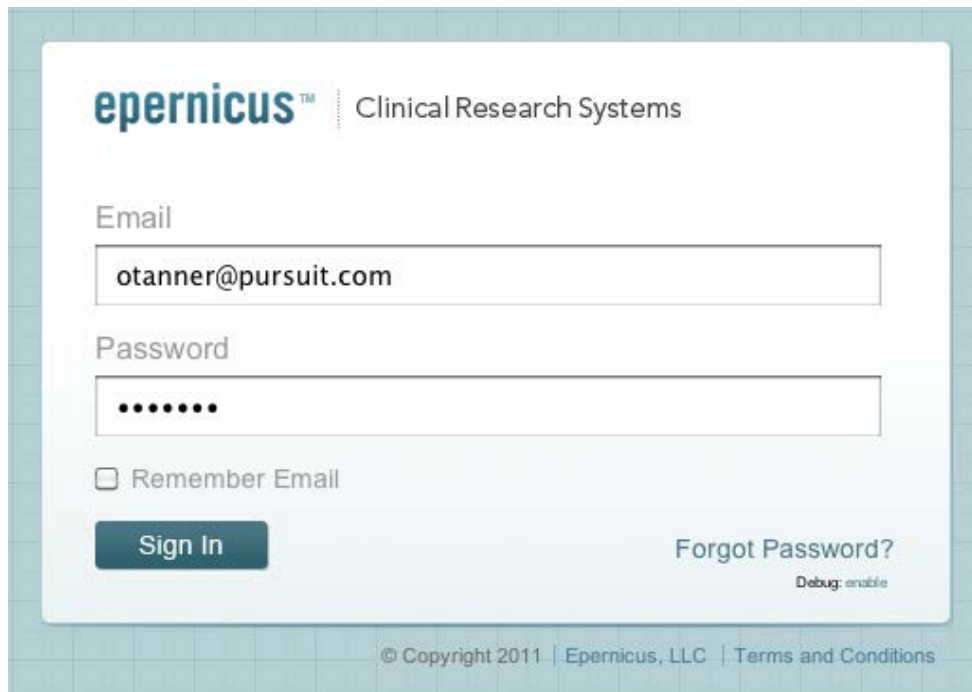
The Field Center will receive emailed quality feedback for every echo submitted to the CICL. In situations where concerns arise regarding the quality of a study submitted by the Field Center, the sonographer and coordinator at the specific field center will receive additional quality feedback and recommendations from the CICL. This feedback will include technical instructions for quality improvement. The CICL may send email queries to the Field Center in cases where additional information or clarification is needed. Field Centers should respond to queries within 3 business days; the query will contain easy to follow instructions for the Field Centers on how to resolve the query. Field Centers should contact the Reading Center with questions related to queries received.

V. Instructions for Electronic Transfer of Studies to the Reading Center

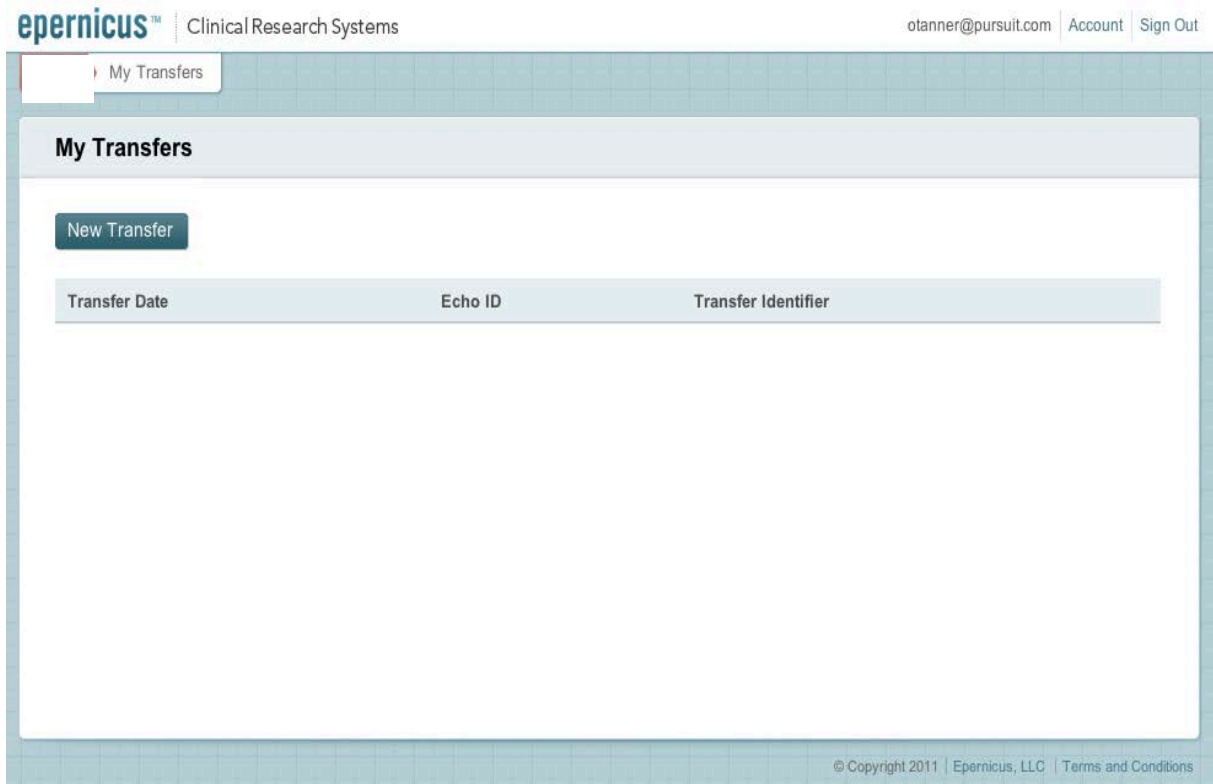
Echocardiograms will be transferred from Field Centers to the Reading Center electronically using secure VPN-based image transfer technology. A dedicated workstation at each Field Center with high-speed internet capability will be set up for study transfers. Field Centers will retain a hard copy of each echocardiogram, stored in a secure location at the Field Center.

Transfer of completed studies to the Reading Center has 2 components:

- (1) Upon finalizing and closing a study on the echo machine, studies will be automatically transferred to the Field Center PC which houses the Tomtec Image Arena software. This will act as a local temporary PACs for recent studies performed at the field center. Image Arena will be configured to automatically forward completed studies to the CICL server via the secure VPN connection.
- (2) For each Echocardiogram study performed and transmitted to the Reading Center, the sonographer must also **separately** submit an electronic Echocardiography Transmittal Form (eETF) to the Reading Center as outlined below. This form provides a notification for the Reading Center to expect the study images and provides important demographic and physiologic (heart rate, blood pressure) information necessary in analyzing the echo studies.
 1. Sign in: Navigate to <https://cicl.clinicalresearchsystems.com> and sign in with your email address and password (provided to you by the Reading Center)

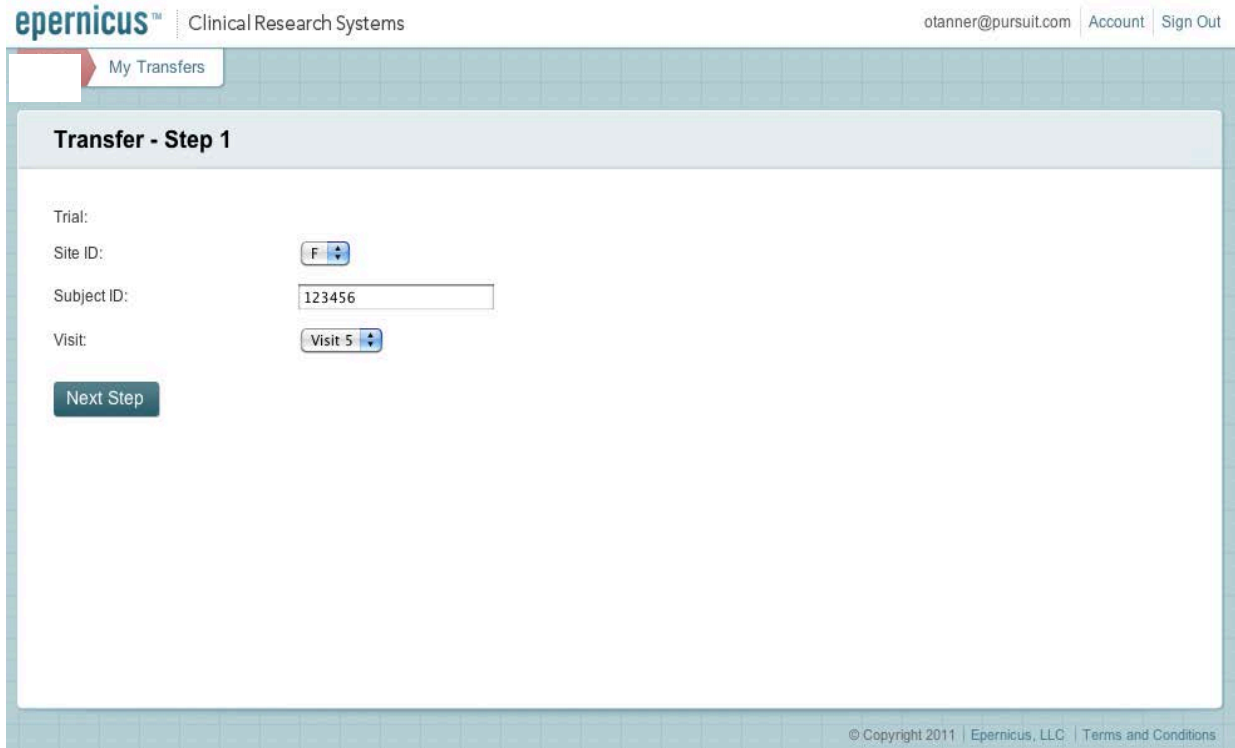


2. Initiate new ETF: Click on “New Transfer” to begin process



3. Enter participant HCHS/SOL ID

- You will select your site identifier and enter the Subject ID. Visit will default to the only available option ('Visit 2')



4. Enter required data

- All fields are required, and are validated according to type. If certain fields are unavailable, you can select 'N/A' from the menu to the right side of that field to indicate that it is intentionally left blank.

Transfer - Step 2

Acrostic ID:	<input type="text" value="FCAT9ROM17"/>	<input type="button" value="v"/>
Gender:	<input type="button" value="Female v"/>	<input type="button" value="v"/>
Echo Date:	<input type="text" value="7"/> <input type="button" value="Apr v"/> <input type="text" value="2011"/>	<input type="button" value="v"/>
Subject DOB:	<input type="text" value="4"/> <input type="button" value="Nov v"/> <input type="text" value="1950"/>	<input type="button" value="v"/>
Subject Age at Encounter:	<input type="text" value="60"/>	<input type="button" value="v"/>
Systolic Blood Pressure (mmHg):	<input type="text" value="120"/>	<input type="button" value="v"/>
Diastolic Blood Pressure (mmHg):	<input type="text" value="80"/>	<input type="button" value="v"/>
Heart Rate (bpm):	<input type="text"/>	<input type="button" value="N/A v"/>
Weight (kg):	<input type="text" value="70"/>	<input type="button" value="v"/>
Height (cm):	<input type="text" value="150"/>	<input type="button" value="v"/>
All required views obtained?:	<input type="button" value="Yes v"/>	<input type="button" value="v"/>
All required views obtained comments:	<input type="text"/>	<input type="button" value="v"/>
Sonographer name:	<input type="text" value="Mark Smith"/>	
Sonographer email:	<input type="text" value=""/> <small>required field left blank</small>	
Notes:	<input type="text"/>	<input type="button" value="v"/>

5. Complete transfer by clicking the 'Complete Transfer' button

6. 'Transfer complete' confirmation screen

- You can initiate another transfer, click on "My Transfers" to view your transfer history

epernicus™ Clinical Research Systems olanner@pursuit.com Account Sign Out

[My Transfers](#)

Transfer - Complete

Transfer Date:	04/07/2011 4:28 PM
ARIC ID:	F123456
Transfer Identifier	3e014d9d

© Copyright 2011 | Epernicus, LLC | Terms and Conditions

For questions regarding either study performance or submission, the Reading Center has an established “hot line” channel of communication, which is listed within the Field Center Manual of Operations.

VI. Instructions for Conducting Studies

A. Echocardiographic Equipment

All echocardiograms will be performed using a dedicated ultrasound system. An acquisition default for the HCHC-SOL study will be programmed in each study echocardiography machine, incorporating the imaging parameters detailed in this section. All examinations should be performed using the ‘HCHC-SOL’ default for subjects in sinus rhythm and the ‘HCHS/SOL AF’ default for subjects in atrial fibrillation. All machines will also be programmed with an HCHS/SOL protocol to guide sonographers through the study protocol and ensure that all protocol required views are obtained.

Default settings for HCHS/SOL are as follows:

2D images	Color Doppler	Spectral Doppler
<ul style="list-style-type: none">▪ H pen▪ Xres: ON▪ Elevation compounding: ON▪ Chroma: 1▪ Gray scale: 4▪ Persistence: low▪ Re-speed in the midline	<ul style="list-style-type: none">▪ Map: 4▪ Smoothing: 3▪ Persistence: OFF	<ul style="list-style-type: none">▪ Compress: 4▪ Reject: 4▪ Speed: 100 mm/sec

Default acquisition time will be 4 cardiac cycles. For patients in atrial fibrillation, select LOOP-TIME which will acquire for 5 seconds (automatic in protocol preset).

B. Subject Identification on Recorded Images

The CICL should receive no subject identifiers, such as the name, on actual echo recordings. **Record only the subject’s study ID.**

C. Subject Preparation

Because many echocardiography measurements are load dependent, each subject’s blood pressure should be taken **just prior** to the echocardiogram and after the subject has been resting for 5 minutes. Blood pressure should be performed in the right arm (unless contra-indicated) with the subject in the supine position using the Omron BP device. Be sure to record the blood pressure and initial heart rate on the electronic Echocardiography Transmittal Form (ETF).

Fill in all of the information on the ETF including heart rate, blood pressure, height, weight, and subject date of birth.

For participants who are unable to have their height and/or weight recorded during the visit (e.g. wheelchair-bound participants), it is acceptable to record the self-reported height and/or weight. Previously recorded height may also be used, if this information is available from Visit 1. Notation of self-reported height and/or weight can be documented in the electronic case report form that is sent to the Echocardiography Reading Center.

Electrocardiographic leads (3-lead) should be placed on the subject prior to imaging. An adequate ECG signal showing a clearly identifiable QRS complex visible on the echocardiographic monitor must be present throughout the imaging exam duration. If a heart rate below 40 bpm or above 100 bpm is detected during the echo examination, the echocardiography sonographer should bring this to the attention of the study clinician on site, so that the participant may be further evaluated by onsite study staff, as needed, according to the protocol outlined in the Field Center Procedures manual.

The subject should be placed in the steep left lateral decubitus position unless this position is not possible.

Echocardiograms should be obtained in a manner that is most consistent with good subject care. Subject care issues, including subject comfort, should always supersede research interests. Indeed, subject cooperation and comfort are extraordinarily important in obtaining the highest quality echocardiographic examination.

VII. Guidelines for Image Optimization

Quantitative measurements entail manually tracing the endocardium and Doppler envelopes at various periods in the cardiac cycle. Even when images are of good quality, this can be extremely difficult, and it is therefore critically important that the best possible endocardial definition and Doppler signal are obtained. Guidelines for obtaining optimal quality 2D, color Doppler, Spectral Doppler, and Tissue Doppler acquisitions are outlined in this section. These general guidelines may be already accounted for in the default HCHS/SOL echo protocols programmed in the Echo machines and are listed here for subjects who may need potential settings modifications for image optimization.

A. General

For patients in sinus rhythm, at least four full cardiac cycles must be recorded for each protocol specified view. For subjects in atrial fibrillation, at least ten full cardiac cycles per view must be recorded. Recording should start when the view is optimized and end after the required number of cardiac cycles have been recorded per view.

The echocardiographic exam should be performed in the order listed in section VII: Echocardiogram Protocol: Required Views.

No measurements should be recorded on the images acquired at the Field Center. All measurements will be performed centrally at the Echocardiography Reading Center.

B. 2D Imaging

Throughout the course of the echo exam, both imaging depth and sector width should be continuously optimized to maintain a frame rate of 50-80 frames per second.

Ensure that the entire cardiac structure of interest is within the echo sector throughout both the systolic and diastolic periods. Optimal visualization of endocardial borders is essential for quantitative analysis. If necessary, increase 2D gain to optimally demonstrate left ventricular endocardial borders, particularly in the apical views. In general, tissue harmonic imaging should be used, except in the unusual situation where this worsens endocardial border definition. Adjustment of sector width, imaging depth, 2D gain, and use of tissue harmonic imaging from the HCHS/SOL protocol defaults may be necessary to optimize image quality and will be at the discretion of the sonographer performing the examination.

Meticulous efforts to avoid foreshortening of imaging planes are essential to the integrity of the quantitative analysis performed on these studies. Utilize the landmarks detailed in the following sections to ensure on axis image acquisition.

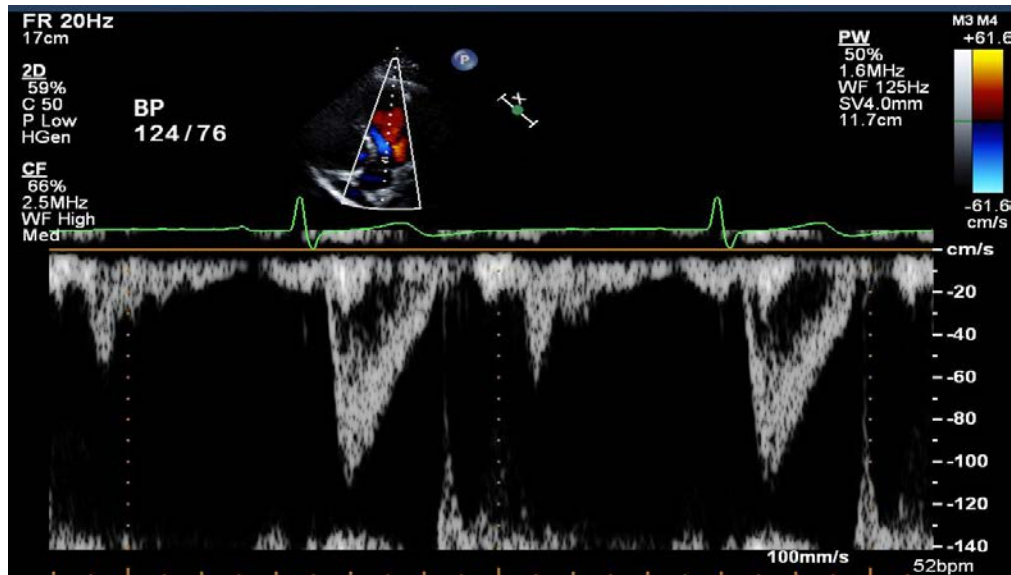
C. Color Doppler Imaging

For all color Doppler imaging, the color Doppler Nyquist limit should be at 64 cm/sec. Color Doppler gain should be set at a level just below the level at which random background noise is seen. Neither color Doppler gain nor the Nyquist limit should be adjusted by the sonographer from the HCHS/SOL protocol default. Color Doppler variance display will not be utilized in this examination.

For all color Doppler acquisitions, be sure to make the color Doppler sample window large enough to encompass the structure of interest, but no larger than necessary.

D. Spectral Doppler


By the Doppler equation, velocity is inversely related to the cosine of the intercept angle between the ultrasound beam and the direction of blood flow. Therefore, the key principle in all spectral Doppler acquisitions (both pulsed wave and continuous wave) is to optimally align the ultrasound beam parallel to the direction of blood flow of interest. Good quality spectral Doppler tracings demonstrate clear onset and end of flow. For pulsed wave Doppler, gain should be optimized such that a well-defined envelope is visible, with a sharp peak and a lucent center. For both continuous and pulsed wave Doppler, sonographers will need to optimize the baseline shift and velocity range such that the spectral envelope occupies approximately three-fourths of display. The following HCHS/SOL protocol defaults will be set and should not be altered: (1) sweep speed 75-100 cm/sec, and (2) sample volume length 3mm [for pulsed wave Doppler].



E. Tissue Doppler Imaging

Tissue Doppler imaging measures the velocity of myocardial tissue, which is low velocity and high amplitude. In contrast, the motion of blood is high velocity and low amplitude and these signals must be filtered. For this protocol, tissue Doppler imaging will be employed to measure annular velocities at both the mitral and tricuspid annulus (described in detail in the sections below). Like standard Doppler, the accuracy of tissue Doppler is dependent on a parallel angle of incidence of myocardial motion with the ultrasound beam. Optimally align the longitudinal motion of the ventricle with the ultrasound beam. Placement of the tissue Doppler sample volume appropriately at the level of annulus (mitral or tricuspid depending on the view being obtained) is essential for high quality data and is reviewed in detail below. Sonographers will need to optimize the baseline shift and velocity range such that the spectral envelope occupies approximately three-fourths of display. The following HCHS/SOL protocol defaults will be set and should not be altered: (1) sweep speed 75-100 cm/sec, (2) sample volume length 5mm, and (3) filter setting of 100 Hz.

Proper positioning of sample volume for mitral annular TDI:



VIII. Echocardiogram Protocol: Required Measures/Views

Blood pressure	
Brachial blood pressure	Measure BP in the right arm (supine) at the beginning of echo examination
Echocardiographic View	Measurement
Parasternal Position	
Parasternal long axis	2D imaging Color Doppler of the mitral valve Color Doppler of the aortic valve 2D focused imaging of the ascending aorta
Parasternal short axis – Aortic valve level	2D imaging PW and CW Doppler of the RVOT
Parasternal short axis – LV mitral valve	2D imaging
Parasternal short axis – Papillary muscle	2D imaging
Parasternal short axis – LV apex	M-mode 2D imaging
Apical Position	
Apical 4 chamber view	2D imaging (including LA) Color Doppler of mitral valve/LA Spectral Doppler (pulse wave and continuous wave) mitral flow TDI of septal and lateral mitral annulus
Apical 4 chamber – focused on the RV	2D imaging (including RA) Color Doppler of tricuspid valve/RA Continuous wave Doppler of tricuspid regurgitation TDI of lateral tricuspid annulus TAPSE of lateral tricuspid annulus
Apical 5 chamber view	2D imaging Pulse wave of LVOT flow Continuous wave of transaortic flow
Apical 2 chamber view	2D imaging (including LA) Color Doppler MV/LA
Apical 3 chamber view	2D imaging
Subcostal View	
Inferior vena cava	2D imaging for 5-10 cardiac cycles M-mode with sniff

IX. Detailed Review of Protocol Required Views

Beginning the Exam

Complete the subject information screen on the echo machine as detailed in the figure below:

The screenshot shows the 'General Information' screen on an echo machine. The screen is divided into several sections: 'General Information', 'Study Type', 'Vitals', 'Medical History', and 'Valve Replacement'. Annotations include a blue box around the name and ID fields, a red box around the birth date, age, and gender fields, and a red box around the vitals and medical history fields. A list of fields to be completed is provided on the right.

1. In the *Last Name* Field, enter 'SOL'

2. In the *First Name* Field, enter 'Echo'

3. In the *Patient ID* Field, enter Participant's SOL ID

Be sure to complete fields for:

- DOB
- Gender
- SBP
- DBP
- Height
- Weight

General Information

Last Name: [] First Name: [] M.I.: [] Birth Date: MM/DD/YYYY Age: [] Gender: [] Patient ID: [] Comments: []

Accession #: [] Sonographer: [] Study Description: [] Ref. M.D.: []

Study Type: Adult Echo

Sys / Dias BP: 124 / 76 MAP: 92 Metric: Height: 5 ft 11 in English: Weight: 185 lb [] oz BSA: 2.04 m²

Smoker: [] Hypertension: [] Hx of Rheumatic Fever: [] Congestive Heart Failure: []

Surgeries: []

Indications:

Murmur: [] Grade: [] Arrhythmia: [] Chest Pain: [] Jugular Venous Distension: [] Dyspnea: [] Peripheral Edema: [] Fatigue: [] Ascites: [] Syncope: [] Infection: [] Dizziness: [] Fever of Unknown Origin: [] Hemoptysis: [] TIA/Stroke: []

Valve Replacement:

Bioprosthetic: Type: [] Date: MM/DD/YYYY

Mechanical: Type: [] Date: MM/DD/YYYY

Pacemaker: []

Be sure to acquire an image of this screen.

A. Brachial Blood Pressure

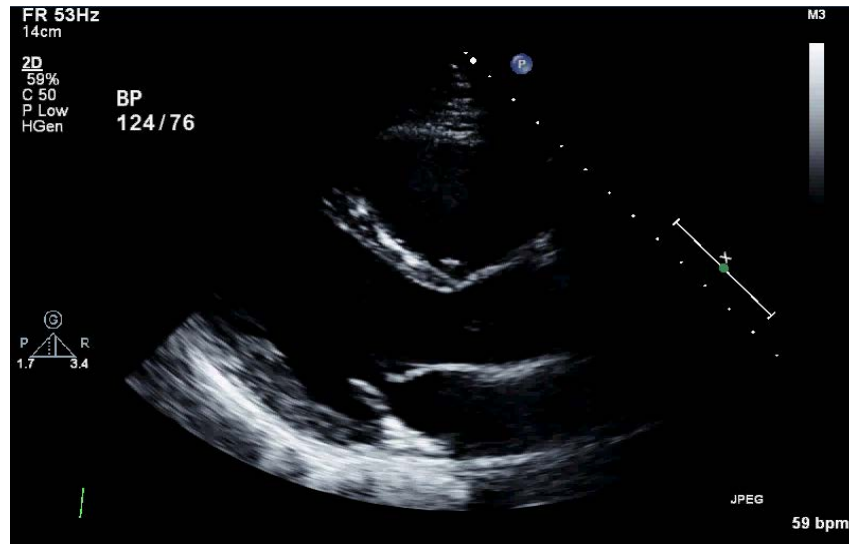
Just prior to the start of the echocardiographic examination, brachial blood pressure is measured. The subject's blood pressure should be taken in their right arm **just prior** to the echocardiogram and after the subject has been resting for 5 minutes (supine position). Be sure to record the blood pressure and initial heart rate on the eETF.

B. Parasternal Views

Three parasternal views will be obtained:

- Parasternal long axis view – standard
- Parasternal long axis view – focus on ascending aorta
- Parasternal short axis view at 4 levels as detailed below (section B.2.)

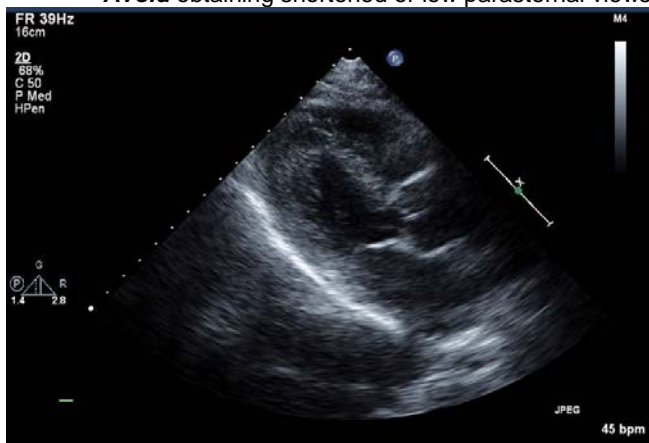B.1.i. Parasternal Long Axis View – Standard View



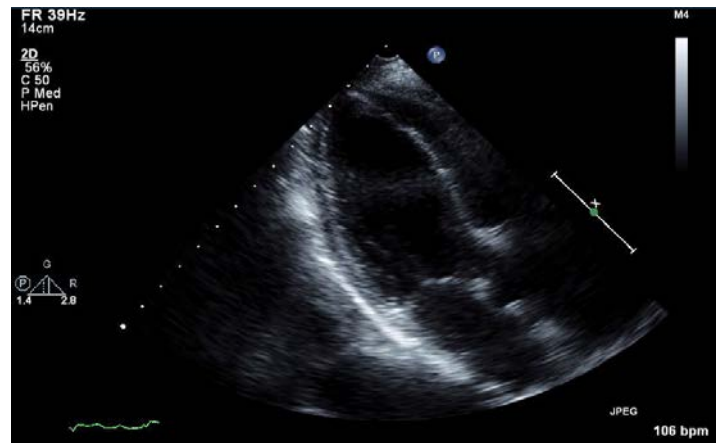In the ideal echocardiographic “window” for the long axis:

- The LV endocardium at the septum and the posterior wall are well delineated.
- The proximal interventricular septum is horizontal and continuous with the aortic root.
- The anterior and the posterior mitral valve leaflets, and the right and noncoronary aortic valve leaflets are visible.
- The left ventricular apex is not visualized.

Avoid obtaining shortened or low parasternal views:



Grossly foreshortened PLAX View



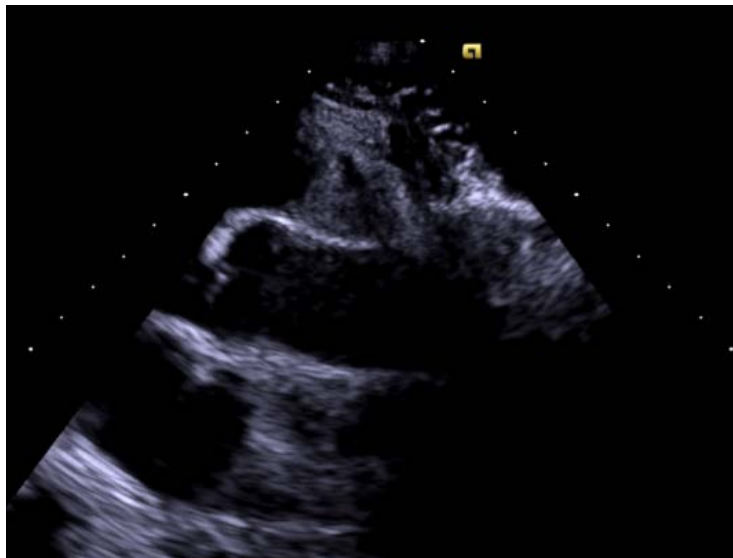
Low PLAX View

B.1.ii. Parasternal Long Axis View – Focus on Ascending Aorta

- Focus on the ascending aorta and slightly decreasing depth and adjusting focus, as needed
- Optimize visualization of the aortic valve leaflets, sinuses of Valsalva, and proximal 2-4 cm of the ascending aorta
- Record 1 cine loop over 3 cardiac cycles in the long axis, and then in the short axis

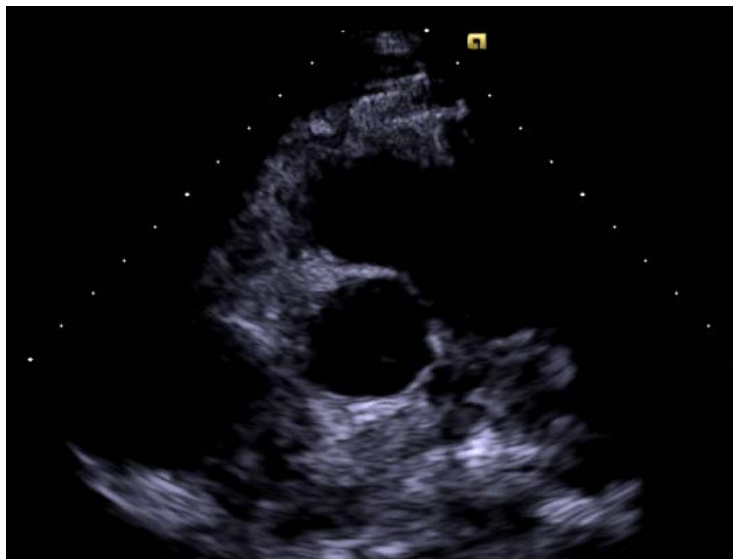Long axis

- Use **HIGH PLAX** view *or* use right parasternal view
- Visualize >2-4 cm length
- Capture \geq 3 cine cycles



Short axis

- Rotate from **HIGH PLAX** view *or* angle above AoV leaflets in PSAX view
- Visualize circumference
- Capture cine cycles

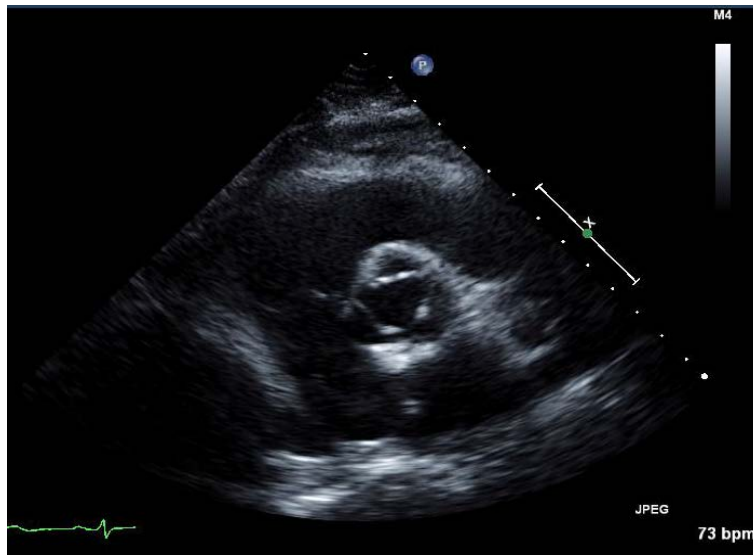

2. Parasternal Short Axis View

Parasternal short axis view will be obtained at four levels:

1. At the aortic valve level with the RVOT and pulmonic valve visible.
2. At mitral valve when both anterior and posterior mitral valve leaflets are visualized.
3. At the mid-papillary muscle level with the papillary muscles visible.
4. At the left ventricular apex.

B.2.i. Aortic Valve Level



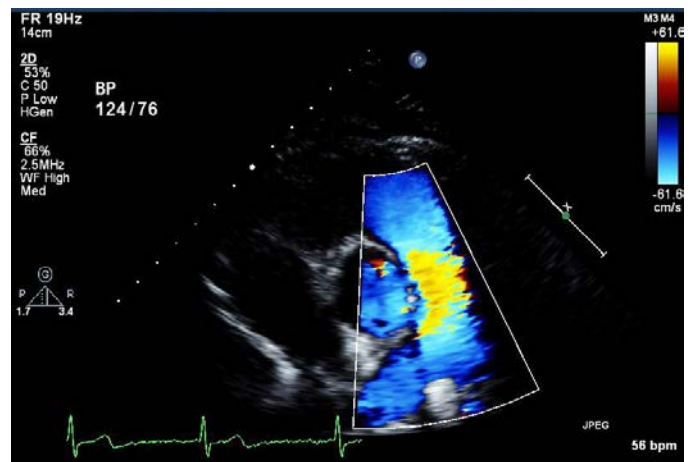
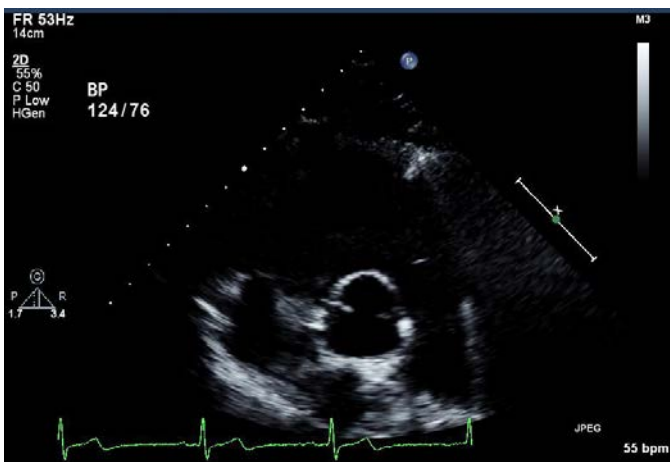Acquire both 2D imaging and color Doppler of this view.

In the ideal echocardiographic “window” for the short axis at the aortic valve level:

- All 3 cusps of the aortic valve are visible, with a clear upside down triangle pattern during systole.
- The tricuspid valve and interatrial septum are visible.

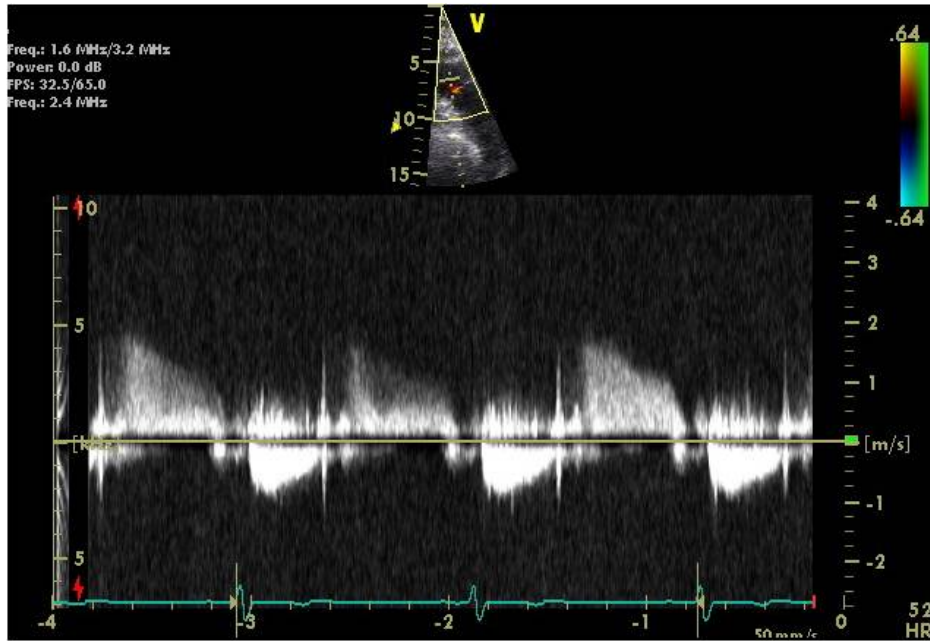
From the parasternal short axis view at the aortic valve level, the following additional images will also be obtained:

- **PSAX view focused on the right ventricular outflow tract and pulmonic valve**

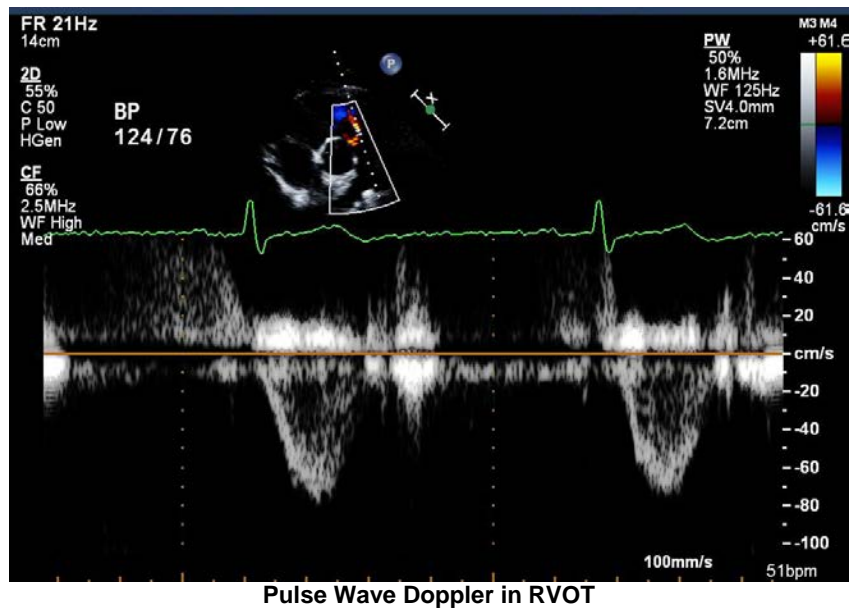


- **Continuous and pulsed wave spectral Doppler of RVOT and trans-pulmonic flow**

- For continuous wave acquisition, ensure that both the antegrade and retrograde Doppler envelopes are optimally visualized. Record a minimum of 3 cardiac cycles (10 for subjects in atrial fibrillation) at a sweep speed of 75-100 mm/sec.



- For pulse wave acquisition, ensure that the sample is in the right ventricular outflow tract (RVOT) approaching the pulmonic valve, just prior to the level of flow acceleration and spectral broadening. Record a minimum of 3 cardiac cycles (10 for subjects in atrial fibrillation) at a sweep speed of 75-100 mm/sec.

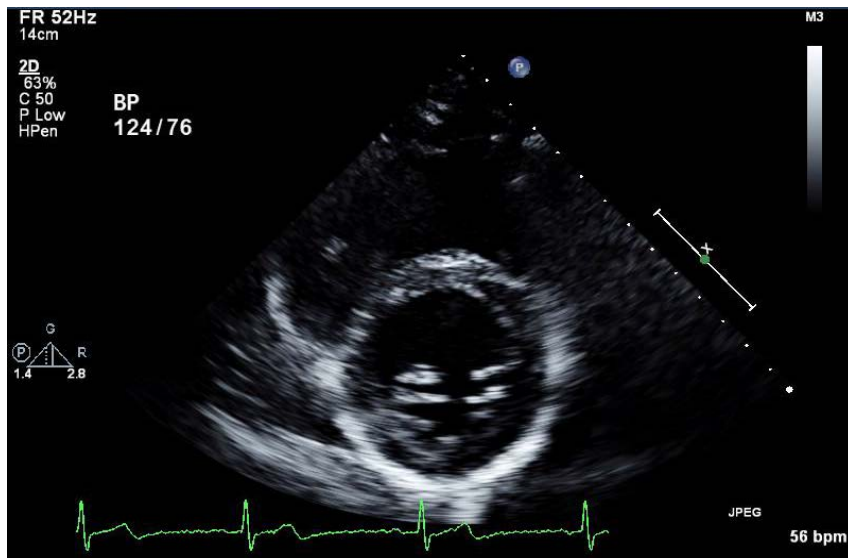


B.2.ii. Mitral valve level, mid-papillary level, and apical level

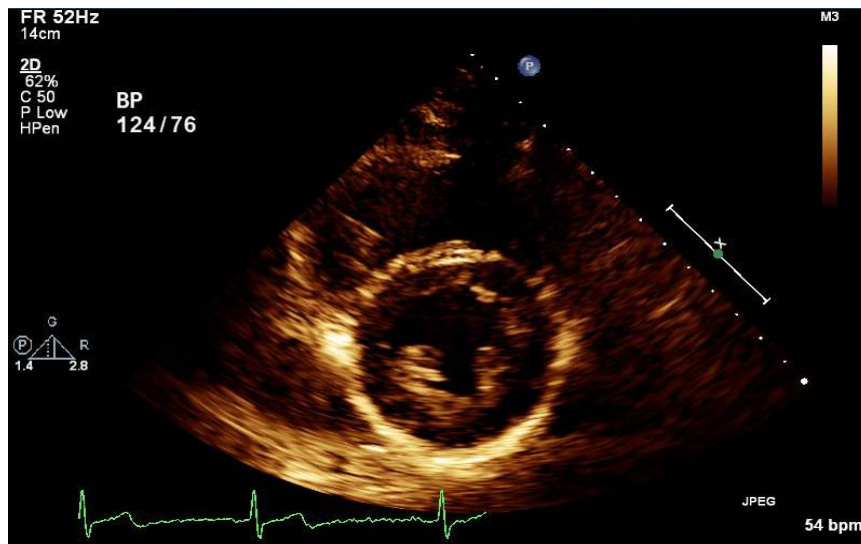
In the ideal echocardiographic “window” for the short axis:

- In the absence of prior infarction, the left ventricle should have a circular shape in the short axis – an elliptical shape suggests off-axis/tangential cut through the ventricle.
- Use internal LV landmarks to ensure imaging at consistent planes in the short axis: visualization of the anterior and posterior mitral leaflets for the mitral valve level; visualization of both papillary muscles for the mid-papillary level
- For all short axis images, adjust sector width and imaging depth to ensure acquisition frame rate of 50 to 70 frames per second.
- Ensure good quality visualization of both the endo-cardium and epi-cardium

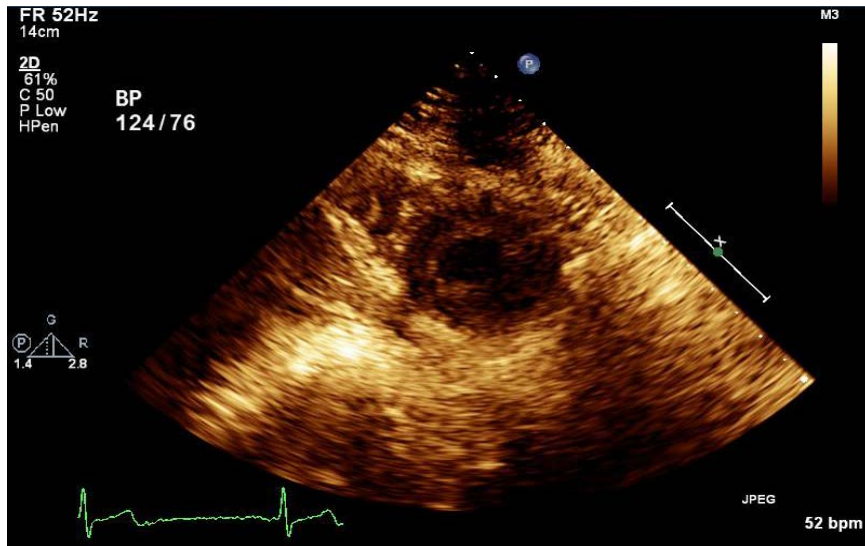
Mitral Valve Level



Mid-papillary Level



Apical Level



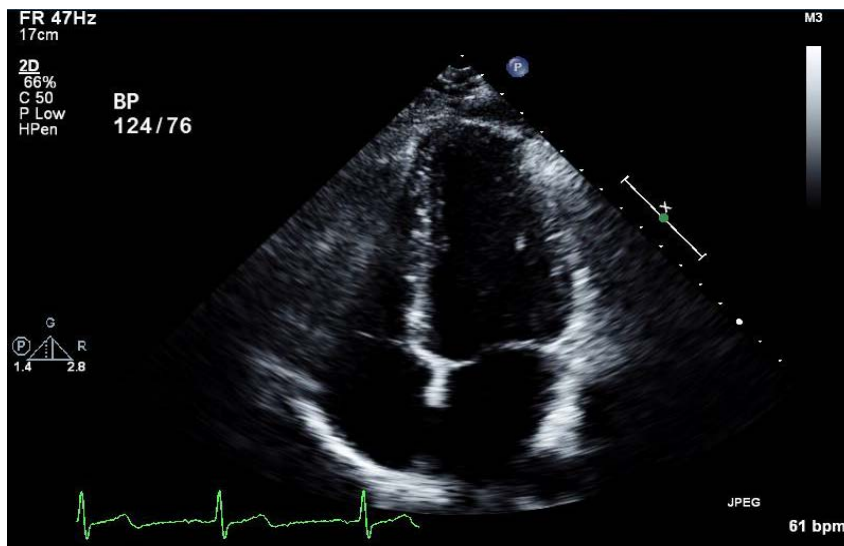
C. Apical Views

Five apical views will be obtained:

- The standard apical four-chamber focused on the LV
- The apical four-chamber dedicated to optimal imaging of the RV
- The five-chamber view
- The two-chamber view
- The three-chamber view

At the Reading center, left ventricular and atrial areas and volumes will be measured from these views (i.e. using Simpson's method). Therefore, in all apical views, special attention should be paid to properly align the image and capture the left ventricle and atrium in full. Avoid either foreshortening or elongating the chambers by transducer angulation.

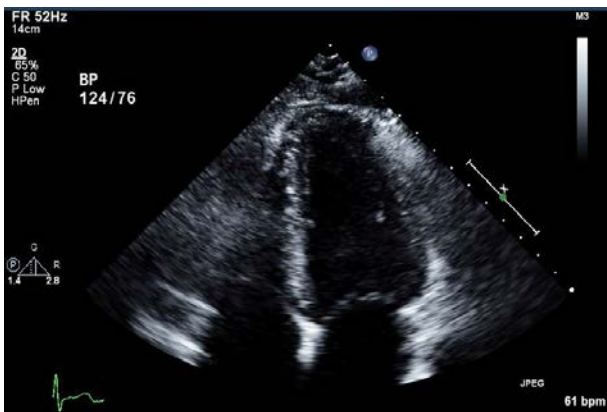C.1. Apical 4-Chamber View



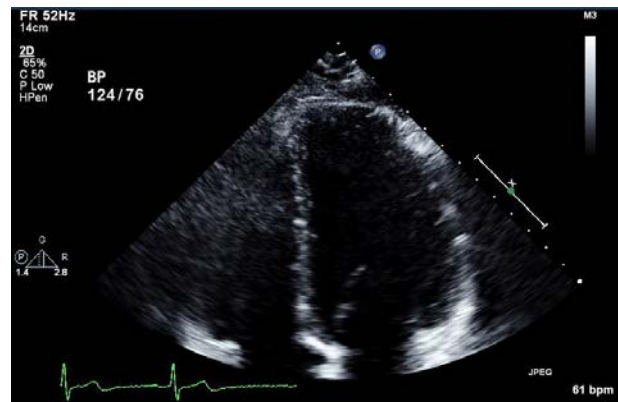
Apical 4-Chamber

C.1.i. Focus on LV

- Obtain 1 clip optimizing visualization of the left ventricle during systole and diastole. Obtain a second clip optimizing visualization of the left atrium throughout systole and diastole.
 - Maximize LV length and be careful not truncate the true long axis.
 - The entire LV endocardium must be within the imaging sector in both end-diastole and end-systole. Pay special attention to the apex and the lateral LV free wall, which are often the most difficult areas to visualize.
 - Adjust sector width and imaging depth to ensure acquisition frame rate of 50 to 70 frames per second.



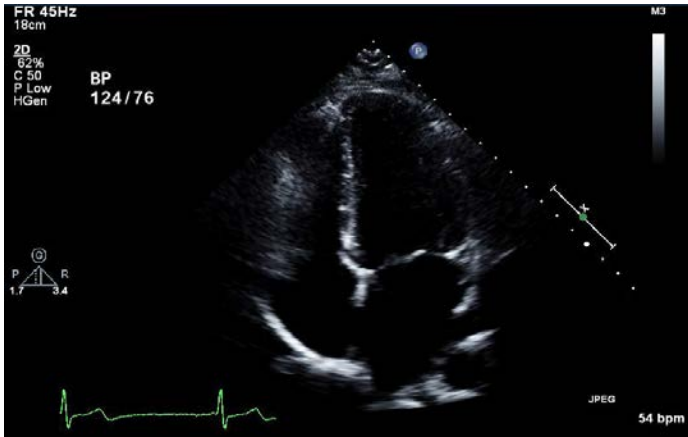Apical 4 Chamber view, at End Systole



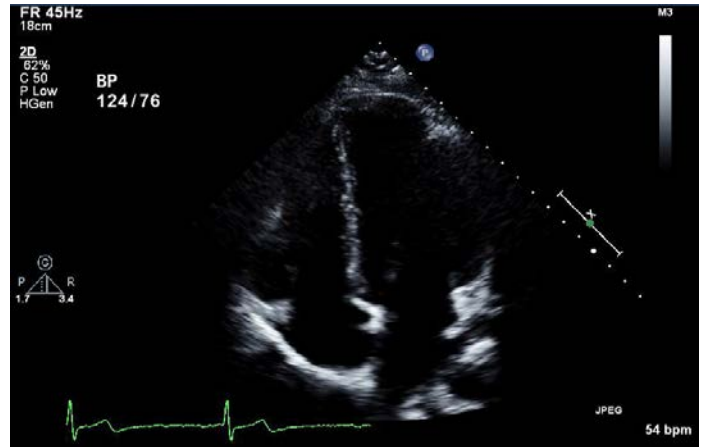Apical 4 Chamber view, at End Diastole

C.1.ii. **Focus on LA**

- Obtain 1 clip optimizing visualization of the left ventricle during systole and diastole. Obtain a second clip optimizing visualization of the left atrium throughout systole and diastole.
 - Properly align the image and capture the left atrium in full. Avoid any foreshortening of the chamber.



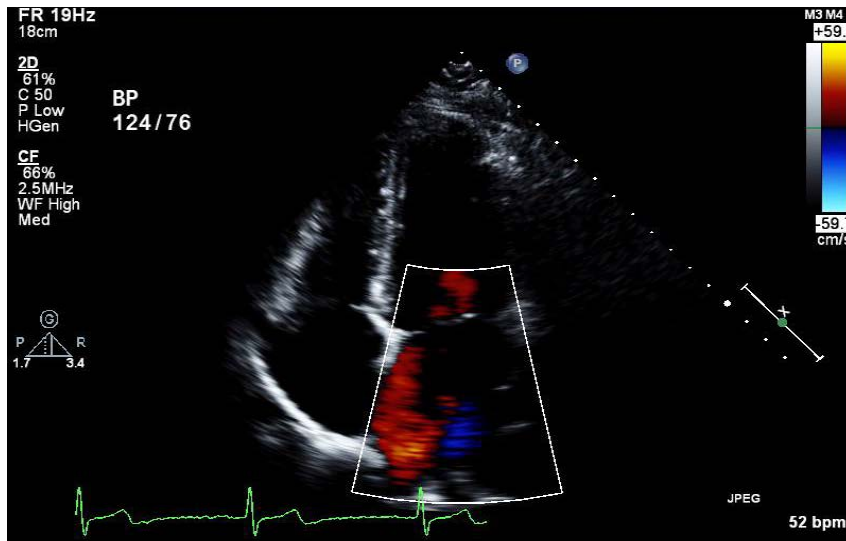
End Systole



End Diastole

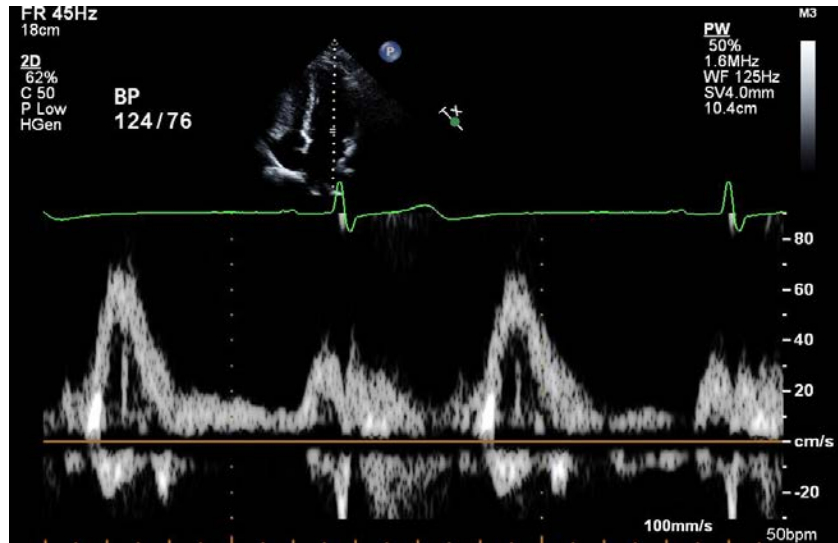
C.1.iii. **Color Flow Doppler for Mitral Regurgitation**

- Adjust color Doppler sample sector over the mitral valve and include the entire LA cavity. To optimize frame rate, keep the color sector scan as narrow as possible, while including the entire LA. The color Nyquist limit is set at 64 cm/s in the HCHS/SOL protocol and should not be altered.



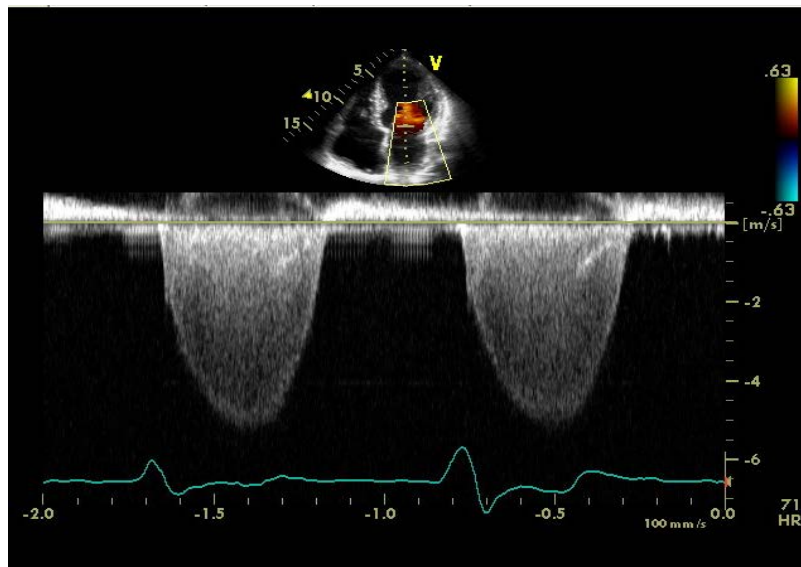
C.1.v. Spectral Doppler of Mitral Inflow

- From the apical four chamber view record the mitral inflow velocity curve with the pulsed-wave Doppler sample volume positioned at the tips of the mitral leaflets during quiet respiration for 30 seconds (or at least five cardiac cycles). Adjust the baseline and Doppler scale to visualize the peak E and A wave velocities. Record a minimum of 3 cardiac cycles (10 for subjects in atrial fibrillation) at a sweep speed of 75-100 mm/sec.



C.1.vi. CW Doppler of the Mitral Regurgitation

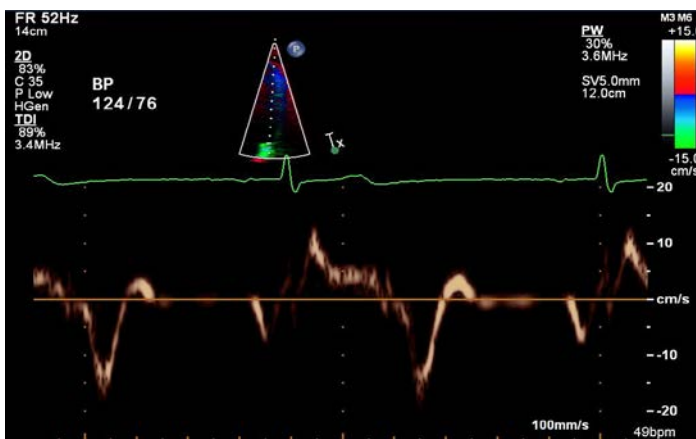
- Position the interrogation line as parallel to the flow as possible. Adjust the baseline and scale to capture the peak MR velocity. Record a minimum of 3 cardiac cycles (10 for subjects in atrial fibrillation) at a sweep speed of 75-100 mm/sec.



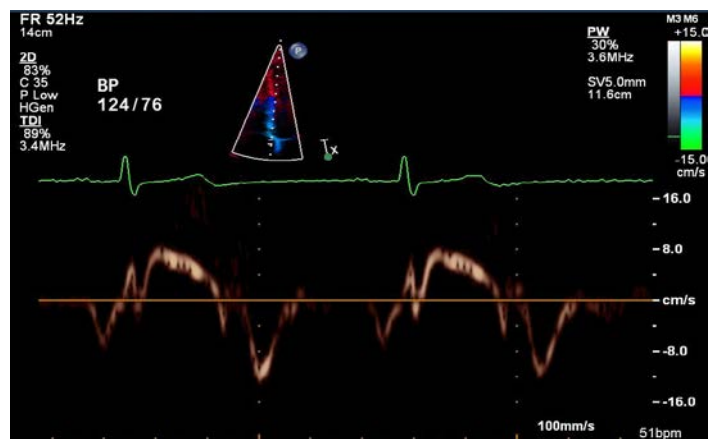C.1.iv. Tissue Doppler Imaging (TDI) of Mitral Annulus (lateral and septal)

1. Decrease image depth (to include the LV and a small part of the LA, ideal depth approximately 16 cm) and optimize the 2D image for the LV, focusing on the lateral wall and the mitral annular region.
2. Adjust the image to orient the motion of the lateral wall parallel to the cursor. Both gains and filter settings should be set low (100 Hz or less) to obtain the best images.
3. Initiate 2D color DTI and position the sample volume on the ventricular side of the lateral mitral annulus at the junction of the LV wall with the mitral annulus of the lateral myocardial segment; the myocardium should stay within the sample volume for as much of the cardiac cycle as possible.
4. Before the data is acquired, check that only the region to be sampled is moving through the sample volume.
5. Switch to PW spectral DTI and set the scale to 20 cm/sec with a sweep speed of 75-100 mm/sec.
6. Before collecting data, set the Pulsed Doppler velocity range to avoid velocity aliasing (a velocity range of +/- 24 cm/sec is normal though subjects with high heart rates may require a higher setting).
7. Once a clear pattern is obtained, record at least 10-20 beats during quiet respiration (or preferably during breath holding at end-expiration).
8. Record a minimum of 3 cardiac cycles (10 for subjects in atrial fibrillation) at a sweep speed of 75-100 mm/sec.
9. Repeat this process for the septal mitral annulus

Proper positioning of sample volume for mitral annular TDI:



Tissue Doppler imaging at the lateral mitral annulus

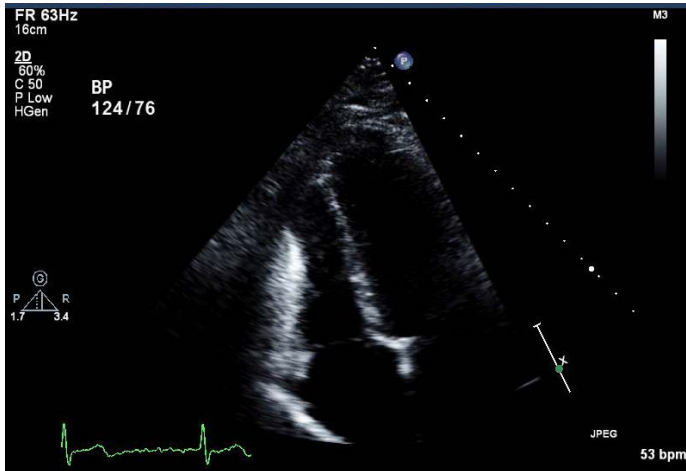

Tissue Doppler imaging at the septal mitral annulus

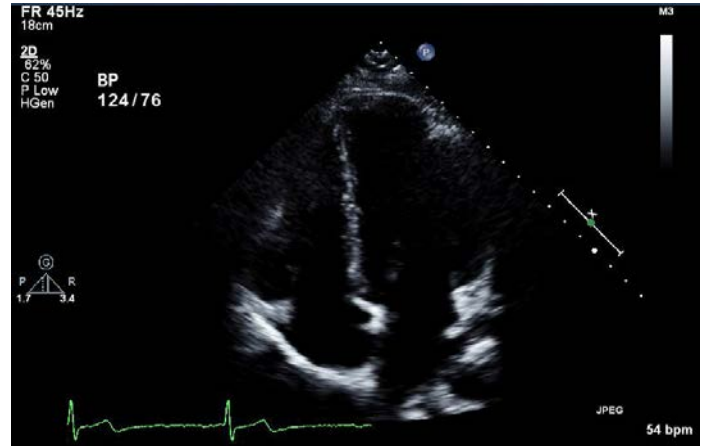C.2. Apical 4-Chamber View (Focused on the Right Ventricle)

In the ideal echocardiographic “window” for the Apical 4-Chamber View focused on the right ventricle:

- The right ventricular length is maximized and the right ventricular apex is clearly visualized. The entire RV endocardium must be within the sector scan in both end-diastole and end-systole.



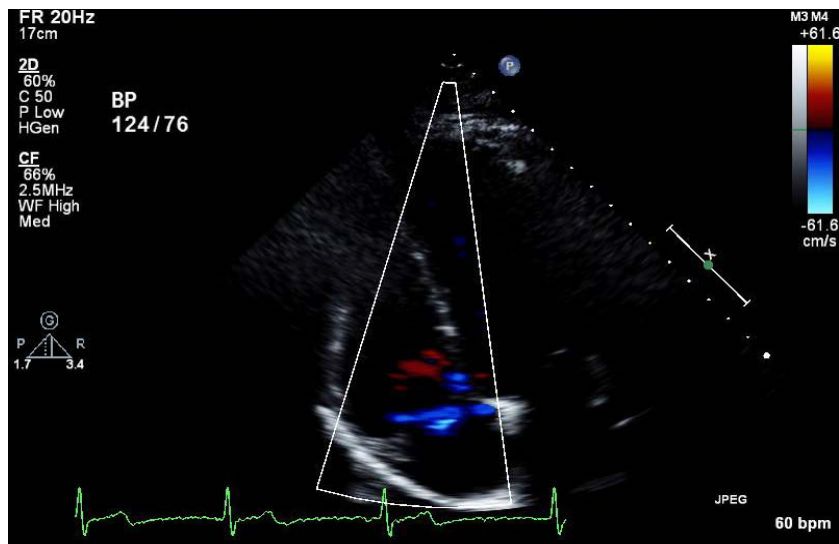
End Systole



End Diastole

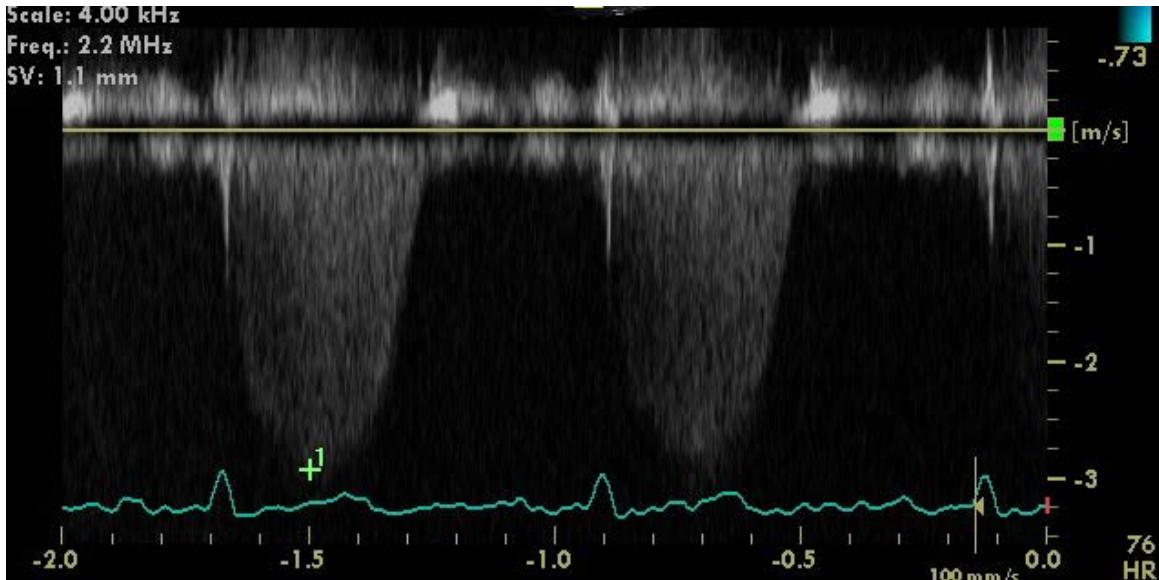
C.2.i. Color Doppler of tricuspid inflow

- Adjust color Doppler sample sector over the tricuspid valve and include the entire RA cavity. The color Nyquist limit is set at 64 cm/s in the HCHS/SOL protocol and should not be altered.



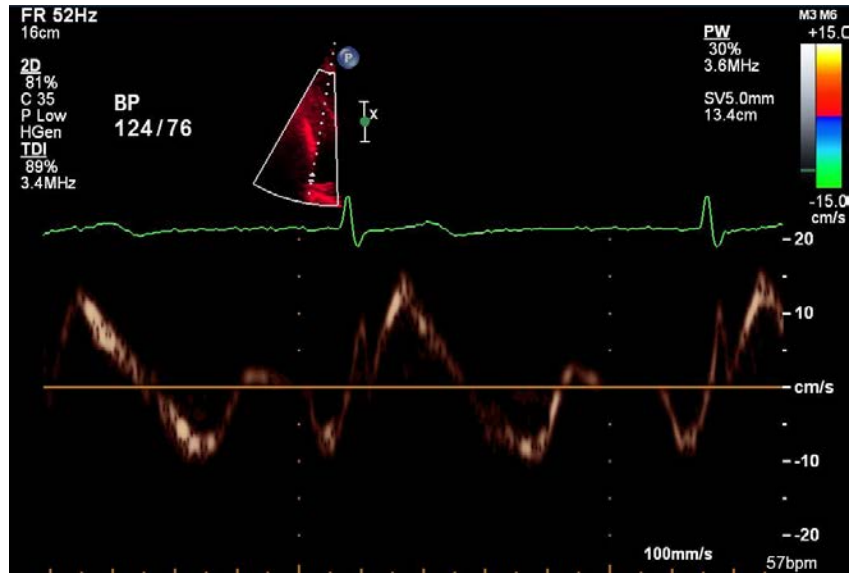C.2.ii. CW Doppler of Tricuspid Regurgitation

- Position the interrogation line down the right ventricle and atrium as parallel to tricuspid regurgitant flow as possible. Adjust the baseline and scale to capture the peak TR velocity. Record at least 3 (10 for subjects in atrial fibrillation) full representative systoles at sweep speed of 75-100 mm/sec.



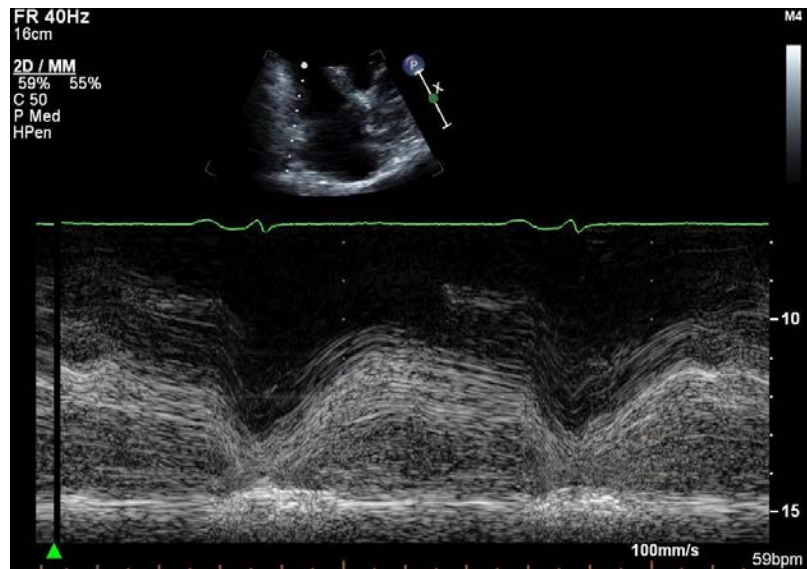
C.2. iii. Tissue Doppler imaging at the lateral tricuspid annulus

- Decrease image depth to include the RV and a small part of the RA (optimal depth approximately 16 cm) and optimize the 2D image for the RV, focusing on the tricuspid annular region.
- Adjust the image to orient the motion of the anterior tricuspid annulus parallel to the cursor. Both gains and filter settings should be set low to obtain the best images.
- Initiate 2D color DTI and position the sample volume on the ventricular side of the lateral tricuspid annulus at the junction of the RV wall with the tricuspid annulus: the myocardium should stay within the sample volume for as much of the cardiac cycle as possible.
- Switch to PW spectral DTI and set the scale to 20 cm/sec with a sweep speed of 75-100 mm/sec. Once a clear pattern is obtained, record at least 10-20 beats during quiet respiration (or preferably during breath holding at end-expiration).
- Record a minimum of 3 cardiac cycles (10 for subjects in atrial fibrillation) at a sweep speed of 75-100 mm/sec.



C.2. iv. TAPSE imaging at the lateral tricuspid annulus

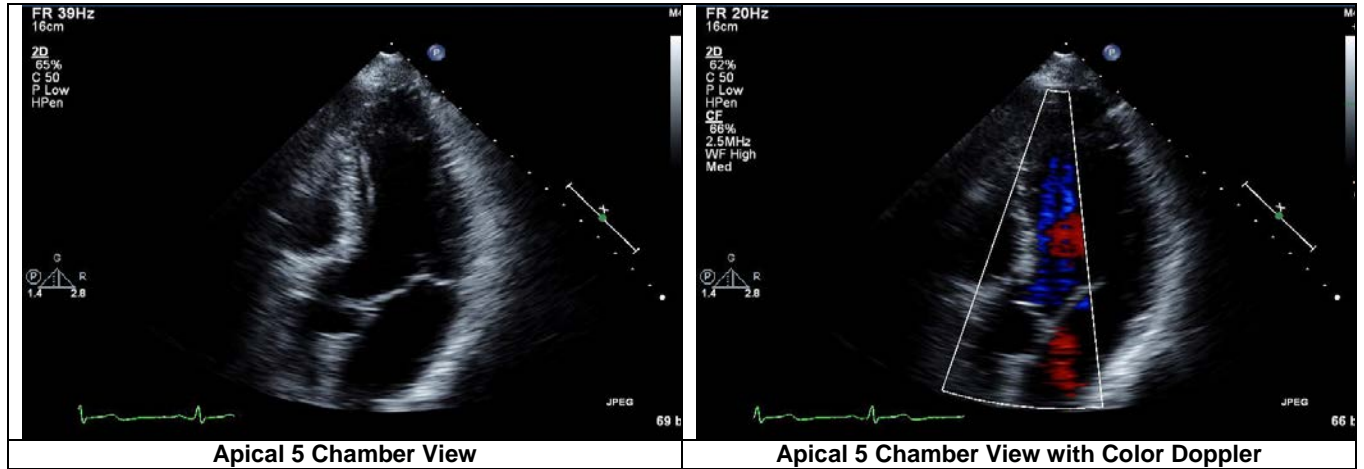
- Switch to M-mode to record tricuspid annular plane systolic excursion
- Ensure that M-mode cursor remains on axis with movement of the lateral tricuspid annulus



C.3. Apical 5-Chamber View

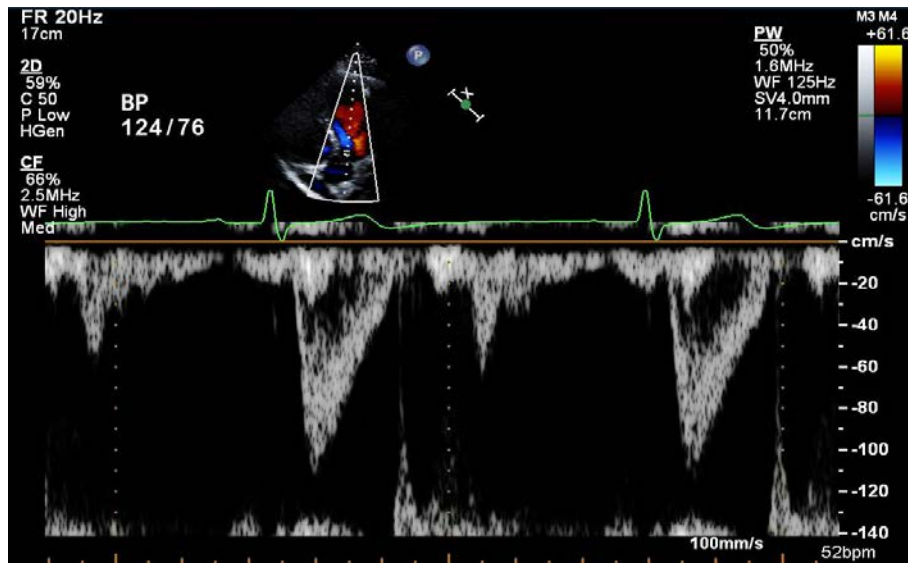
In the ideal echocardiographic “window” for the Apical 5-Chamber View:

- Maximize LV length, making sure not to truncate the true long axis.

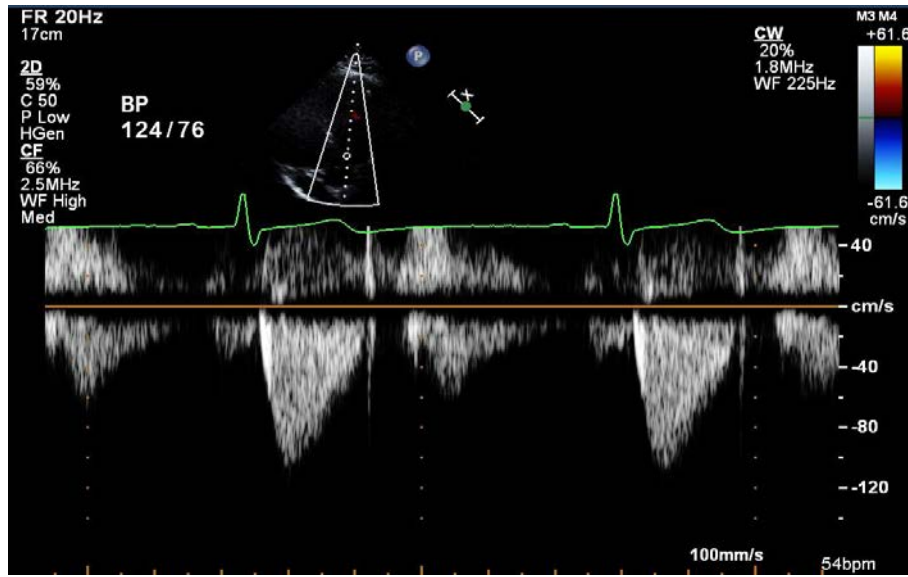


C.3.i. Pulsed wave Doppler at the left ventricular outflow tract

- For pulse wave acquisition, ensure that the sample is in the left ventricular outflow tract (LVOT) approaching the aortic valve, just prior to the level of flow acceleration and spectral broadening. Record a minimum of 3 cardiac cycles (10 for subjects in atrial fibrillation) at a sweep speed of 75-100 mm/sec.

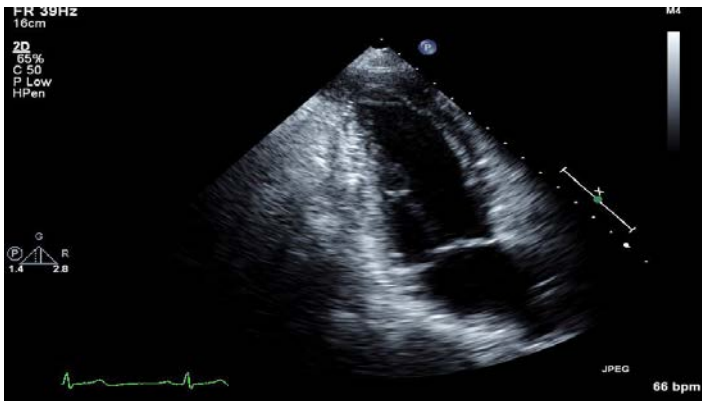

C.3.ii. Continuous wave Doppler across the aortic valve

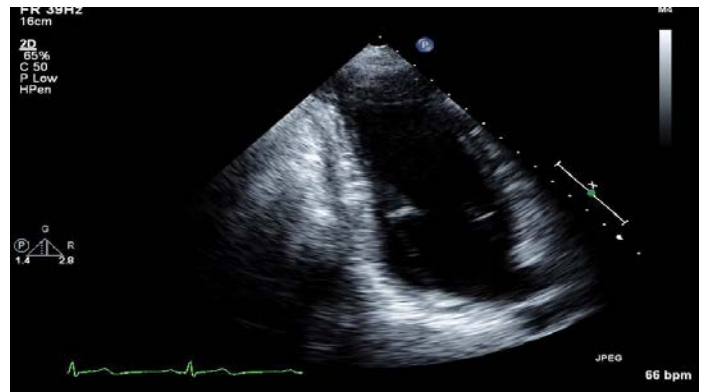

C.4. Apical 2-Chamber View

- Obtain 1 clip optimizing visualization of the left ventricle during systole and diastole.
 - Maximize LV length and be careful not truncate the true long axis.
 - The scan plane transects the anterior and inferior LV walls, with neither the RV nor the LV outflow tract visualized.
 - The most difficult areas in which to visualize the endocardium are usually the anterior LV wall and the apex; pay particular attention to these walls. Visualization of both anterior and inferior wall endocardium will be essential to accurately calculate left ventricular volume by Simpson's formula.
 - Adjust sector width and imaging depth to ensure acquisition frame rate of 50 to 70 frames per second.

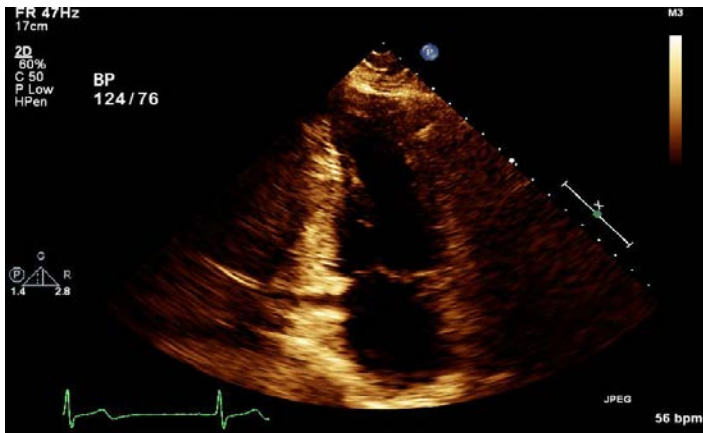


End Systole

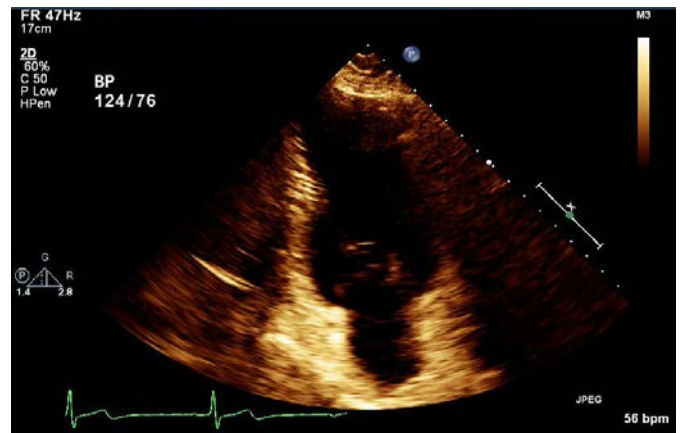


End Diastole

- Obtain a second clip optimizing visualization of the left atrium throughout systole and diastole.
 - Special attention should be paid to properly aligning the image and capturing the left atrium in full. Avoid any foreshortening of the chamber.



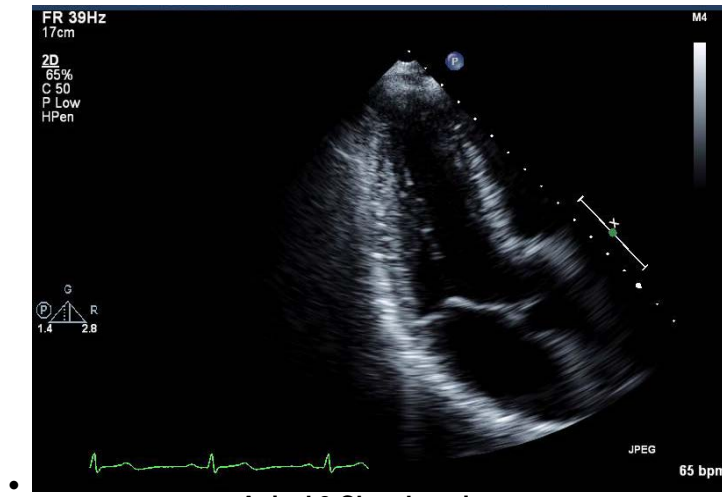
End Systole



End Systole

C.5. Apical Three Chamber View:

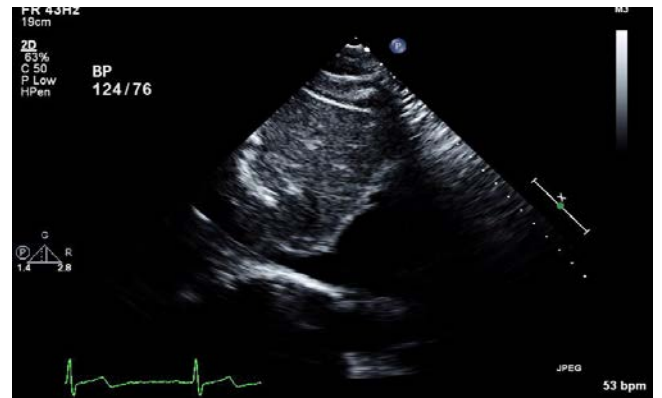
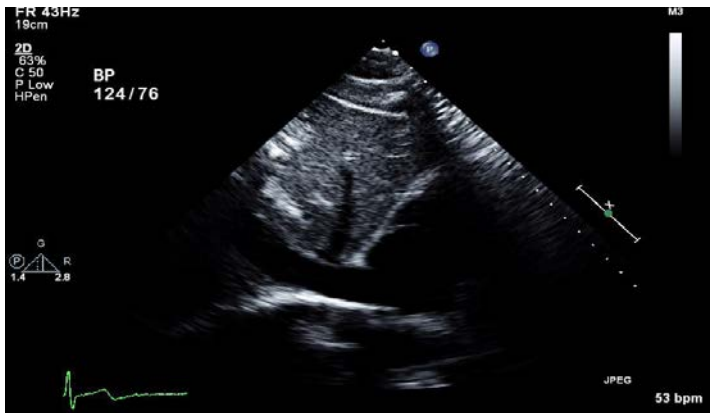- Obtain a 2D image, including the entire LA and LV and mitral valve



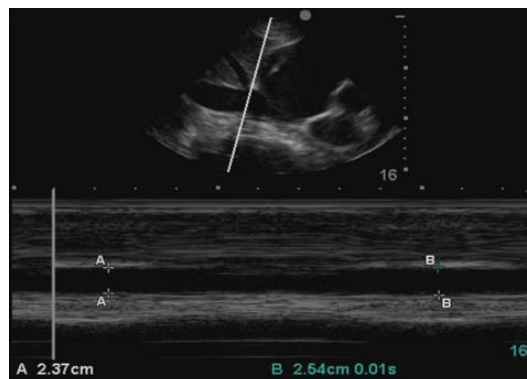
Apical 3 Chamber view

D. Sub-costal View

This view is obtained from the sub-xiphoid position with the transducer manipulated to visualize the proximal inferior vena cava where it meets the right atrium. Approximately 5-10 beats should be acquired in this view to allow for assessment of both IVC size and change in diameter with respiration.



When obtaining M-mode, place the M-mode cursor 1-2 cm from the cavo-atrial junction, then image with and without SNIFF:



X. Reporting of Critical Results

Sonographers performing echocardiographic studies will occasionally identify abnormalities that they consider important and will alert site investigators directly. These findings will include, but are not limited to, tamponade, aortic dissection, thrombosed or frankly dysfunctional prosthetic valve, pseudoaneurysm, intracardiac abscess or obvious vegetation, intracardiac thrombus, ventricular septal defect, and intracardiac mass/tumor. The Echocardiography Reading Center will also be informed via a “critical alert” checkbox and a free text field in the electronic Echocardiography Transmittal Form (ETF) to facilitate an expedited analysis of the study. Site investigators will be responsible for handling alert findings (either as alerts requiring emergency/immediate referral, urgent referral, or routine referral as they deem appropriate), including relaying findings to study participant and, where consent has been provided, to the participant’s treating provider. We recommend that each site establish a system that allows the site sonographer to communicate directly with the local consultant cardiologist (in person or by phone) with joint review of the echo images, as needed, to verify presence of a possible critical alert and coordinate with clinic staff the most appropriate course of action for the participant. Possible and/or verified critical alerts will be expedited for review by the Echocardiography Reading Center.

Other abnormalities that may be detected by the sonographer (in conjunction with the consultant cardiologist, as needed) that would be considered a non-critical alert include: a) low EF $\leq 30\%$; b) pericardial effusion $> 1\text{cm}$, without hemodynamic compromise; c) flail MV leaflet with severe mitral regurgitation; d) other severe valvular disease (aortic, mitral, tricuspid, or pulmonic); e) hypertrophic cardiomyopathy with evidence of obstruction; f) severe pulmonary HTN with PASP $> 70\text{ mmHg}$; g) large aortic aneurysm with ascending aorta $> 50\text{ mm}$ diameter; and, h) complex congenital heart disease. Non-critical alerts can also include non-cardiovascular findings that could benefit from nearer term medical attention (e.g. possible liver mass). These findings are not considered true critical alerts but, if identified, will also be expedited for review by the Echocardiography Reading Center.

Over-reading cardiologists at the Echocardiography Reading Center may identify critical abnormalities that would require emergent notification and arrangements for care. Such findings will be reported within 24 hours of review by the Reading Center to the Data Coordinating Center and will be communicated to the field centers as an Immediate Alert Notification. Abnormalities that would trigger a critical result include, but are not limited to a) tamponade, b) aortic dissection, c) thrombosed or frankly dysfunctional prosthetic valve, d) pseudoaneurysm, e) intracardiac abscess or obvious vegetation, f) intracardiac thrombus, g) ventricular septal defect, and, h) intracardiac mass/tumor. Each field center should have a plan for handling these types of alerts, including relaying findings to study participant and, where consent has been provided, to the participant’s treating provider.

Over-reading cardiologists at the Echocardiography Reading Center may identify specific non-critical abnormalities that would be important for a patient and physician to be aware of, but that don’t necessarily require emergent care. These findings will be incorporated into the routine data transfers from the Echocardiography Reading Center directly to the Data Coordinating Center. Such findings include the items listed above as “non-critical” alerts in addition to: a) moderate or greater mitral regurgitation, b) moderate or greater mitral stenosis, c) moderate or greater obstructive lesions of left ventricular outflow, including aortic stenosis and dynamic left ventricular outflow tract obstruction, d) moderate or greater aortic regurgitation, e) moderate to severe pulmonary hypertension, f) severe right ventricular enlargement.

Limited quantitative data will be included in the routine reporting letter generated by the data coordinating center for all participants. This will include three commonly used measures of cardiac structure and function: a) left ventricular ejection fraction, b) left ventricular diastolic diameter, c) left ventricular wall thickness. These data will be presented in a table with reference values (see example below).

Parameter	Value	Sex	Low Normal	Mildly Abnormal	Moderately Abnormal	Severely Abnormal
LV ejection fraction (%)	[VALUE]	Both	50 – 54	45 – 49	30 – 44	< 30
LV diastolic diameter (cm)	[VALUE]	Men		6.0-6.3	6.4-6.8	≥ 6.9
		Women		5.4-5.7	5.8-6.1	≥ 6.2
LV wall thickness (cm)	[VALUE]	Men		1.1-1.3	1.4-1.6	≥ 1.7
		Women		1.0-1.2	1.3-1.5	≥ 1.6

Reference values are based on practice guidelines published by the American Society of Echocardiography.¹

¹ Lang RM, Bierig M, Devereux RB, Flachskampf FA, Foster E, Pellikka PA, Picard MH, Roman MJ, Seward J, Shanewise JS, Solomon SD, Spencer KT, Sutton MS, Stewart WJ. Recommendations for chamber quantification: a report from the American Society of Echocardiography’s Guidelines and

XI. Contact Information

For technical echo-related questions, please direct all questions and inquiries to the Brigham and Women's Hospital Cardiac Imaging Core Lab:

Project Coordinator: Karen Smith / Aria Rad
Telephone: 1-617-525-6730
Fax: 1-617-582-6027
Email: echocore@rics.bwh.harvard.edu
HCHS/SOL Echocardiographic Imaging Core Laboratory
PBB Ground Rm A-100
20 Shattuck Street
Boston, MA 02115

Standards Committee and the Chamber Quantification Writing Group, developed in conjunction with the European Association of Echocardiography, a branch of the European Society of Cardiology. J Am Soc Echocardiogr. 2005;18(12):1440-63.